

Henry Ford Hospital Medical Journal

Volume 32
Number 4 *First International Workshop on
MEN-2*

Article 8

12-1984

Screening for Hereditary Medullary Cancer in Denmark

Kristian Emmertsen

Follow this and additional works at: <https://scholarlycommons.henryford.com/hfhmedjournal>



Part of the [Life Sciences Commons](#), [Medical Specialties Commons](#), and the [Public Health Commons](#)

Recommended Citation

Emmertsen, Kristian (1984) "Screening for Hereditary Medullary Cancer in Denmark," *Henry Ford Hospital Medical Journal* : Vol. 32 : No. 4 , 238-243.

Available at: <https://scholarlycommons.henryford.com/hfhmedjournal/vol32/iss4/8>

This Article is brought to you for free and open access by Henry Ford Health System Scholarly Commons. It has been accepted for inclusion in Henry Ford Hospital Medical Journal by an authorized editor of Henry Ford Health System Scholarly Commons.

Screening for Hereditary Medullary Cancer in Denmark

Kristian Emmertsen, MD*

Screening of first-degree relatives of patients with medullary thyroid cancer (MTC) gave normal values of pentagastrin-stimulated serum calcitonin and 24-hour urinary catecholamine levels in the relatives of 18 of 22 patients. This result is considered to be valid evidence for sporadic MTC. Absence of C-cell hyperplasia may be another indication of sporadic MTC. Four hereditary MTCs were represented by one fully expressed MEN-2B patient without affected relatives, one fully expressed

MEN-2A case in one family, and two first cousins with MTC as the only MEN-2A lesion in another family. Fourteen relatives of the MEN-2A patients had elevated serum calcitonin levels, and eight additional cases were detected during a subsequent prospective survey. No linkage to genetic markers was found in one MEN-2A family, and no deletion within band 20p12.2 was found in seven MEN-2A affected individuals in the two families.

Screening for hereditary medullary cancer of the thyroid (MTC) raises two different questions. First, when a patient appears with MTC, how are the hereditary and sporadic varieties of the tumor differentiated? Second, when the hereditary form of MTC as part of an MEN-2 syndrome is proven, how should future studies and treatment of affected family members be handled?

Differentiation Between Hereditary and Sporadic MTC

Family screening

Since neither a negative family history nor absence of associated MEN-2 lesions in the patient proves the sporadic variety of MTC, we routinely examine all first-degree relatives. The investigation includes the determination of basal and pentagastrin-stimulated serum immunoreactive calcitonin for diagnosis of MTC, determination of 24-hour urinary catecholamine excretion for diagnosis of pheochromocytomas, and inspection for multiple mucosal neuromas. We applied this family screening program to 92 first-degree relatives of 22 patients with MTC who had no known familial occurrence of the disease.

Normal results obtained in all first-degree relatives of 18 of these 22 patients are considered to be evidence for the sporadic variety of MTC in these patients. Due to the dominant mode of inheritance and variable age of expression of MEN-2, this conclusion seems most valid in larger families, especially when both parents of the index patient have been examined. When one or both parents are dead and only a few other first-degree relatives are available for investigation, the conclusion that the disease is the sporadic variety may be wrong. However, even in large families, a diagnosis of hereditary MTC may be missed if the index case represents a new mutation, and the offspring are few or young. At

present we do not know the frequency of new mutations leading to hereditary MTC. Thus, there are limitations to the validity of a conclusion that a given patient has the sporadic variety of MTC based only on normal screening results in first-degree relatives. However, for psychological and practical reasons, we accepted this risk of missing a diagnosis of hereditary MTC and when the results of initial screening were normal, we did not screen the relatives further.

Four of the 22 index cases of MTC were of the hereditary variety, as evidenced by family screening in two cases and by the presence of associated MEN-2 lesions in two.

In other series, family screening to differentiate hereditary and sporadic varieties of MTC has demonstrated a similar prevalence of 10-25% for the hereditary variety (1-3). Although family screening is useful, it is expensive and time consuming and creates anxiety in relatives as well. Furthermore, a conclusion that the patient has sporadic MTC may not be valid ultimately.

Histopathology

Sporadic MTC is usually a unicentric tumor, whereas hereditary MTC is a multicentric lesion with tumors in both thyroid lobes. However, this bilateral involvement of the thyroid may not be evident on clinical examination. Hemithyroidectomy for an apparently unilateral thyroid lump of unclassified variety is often

Submitted for publication: July 24, 1984

Accepted for publication: December 13, 1984

Department of Nuclear Medicine and Radium Centre, Aarhus Kommunehospital, Denmark

Address reprint requests to Dr. Emmertsen, Department of Nuclear Medicine and Radium Centre, Aarhus Kommunehospital, DK-8000, Aarhus C, Denmark.

Supported by Grant 6/80 from the Danish Cancer Society

performed before its MTC characteristics become evident by histopathological examination; and ascertaining bilaterality of the tumor is impossible at that point.

It is impossible to differentiate between hereditary and sporadic MTC by any histopathological characteristics of the tumor cells themselves. However, diffuse hyperplasia of C-cells is probably a prerequisite histopathological event only of the hereditary variety of MTC. Using an immunoperoxidase technique for demonstration of calcitonin, we found that C-cells were present in clusters exceeding 20 cells in hereditary MTC, whereas in cases classified as sporadic by family screening, C-cells were sparse and never occurred in clusters exceeding five cells (4). Similar results have been reported in larger series (3,5), suggesting that C-cell hyperplasia can differentiate hereditary from sporadic MTC.

We recently found a discrepancy between the histopathological results and results of family screening. C-cell hyperplasia was demonstrated in a 43-year-old man with MTC but no associated MEN-2 lesions. Screening results from his mother, two children (8 and 13 years old), three brothers, and five nephews or nieces were normal, and his father had died at age 74 without clinical evidence of a thyroid malignancy. MTC in this patient could be hereditary, either inherited from his father or caused by a new mutation. Alternatively, C-cell clusters of more than 20 cells may be an extreme range of normal, as suggested by the autopsy series of Gibson, et al (6); thus, hyperplasia could occur in sporadic MTC. Hence, the hereditary variety of MTC may not be the correct identification for all cases of MTC associated with C-cell hyperplasia. On the other hand, since cases of hereditary MTC without associated C-cell hyperplasia have not been reported, the absence of C-cell hyperplasia in appropriate thyroid sections seems to be a reliable marker for the sporadic variety. Family screening may therefore not be necessary in such cases.

Management of Hereditary MTC

MEN-2A, Family I

Initial study

Two patients with MTC among the 22 index patients were related as first cousins in a large family (Fig. 1). Neither was aware of the disease in the other, and the relationship became evident to us during the initial family screening. It was further revealed that a brother of one subject was treated at another institution for MTC and that during a fallopian tube resection in 1966

another first cousin had developed a nearly fatal hypertensive crisis. Subsequently, a pheochromocytoma had been removed. The initial family screening in 1979 (7) revealed elevated serum calcitonin levels in 11 asymptomatic family members aged 15-78 years, including the patient with previous pheochromocytoma. Thyroidectomy was undertaken in nine but not performed in two due to age and severe rheumatic valvular heart disease. All thyroid glands that were removed contained multicentric MTC.

Prospective study

After this initial study, we undertook a prospective survey with annual surveillance of all family members at risk. Basal serum calcitonin determinations were initiated for young children at age five. Pentagastrin stimulation and 24-hour urinary catecholamine determinations were included from age nine to age 55 before excluding the diagnosis of MEN-2A carrier state on the basis of normal results. After publication of the data of Gagel, et al (8) indicating that the MEN-2A carrier state is almost invariably evident before age 35, we curtailed monitoring family members beyond this age. We have hesitated to administer pentagastrin to small children because it can cause discomfort at times.

During the prospective survey, we detected elevated pentagastrin-stimulated serum calcitonin levels (above the normal range and at least twice the basal value) in eight family members who had normal values at the initial study (Fig. 2). However, when the radioimmunoassay for calcitonin used at the initial study (9) was replaced in May 1981 by a more sensitive procedure (10), elevated levels were found in seven of the eight subjects, and a borderline value was obtained in the eighth. Since the improved sensitivity of the new calcitonin radioimmunoassay contributed to this apparent conversion of normal to elevated values, it is important to be aware of the quality of the radioimmunoassay when MEN-2 families are screened. Our results do not provide valid information about the ages at which the conversion took place. During the prospective study period, the serum calcitonin levels generally increased in three subjects, whereas no consistent changes were observed in the remaining five subjects (Fig. 2). Individual variations in calcitonin levels were observed in all subjects, in agreement with results reported by Graze, et al (11). Lack of precision of the radioimmunoassay cannot fully explain this variability, and periodic changes may occur in the secretory capacity of C-cells. Because the level of serum calcitonin peaks within five minutes after pentagastrin is injected, slight variation in the sampling time or in the velocity of blood flow in the vein used could also account for some variability.

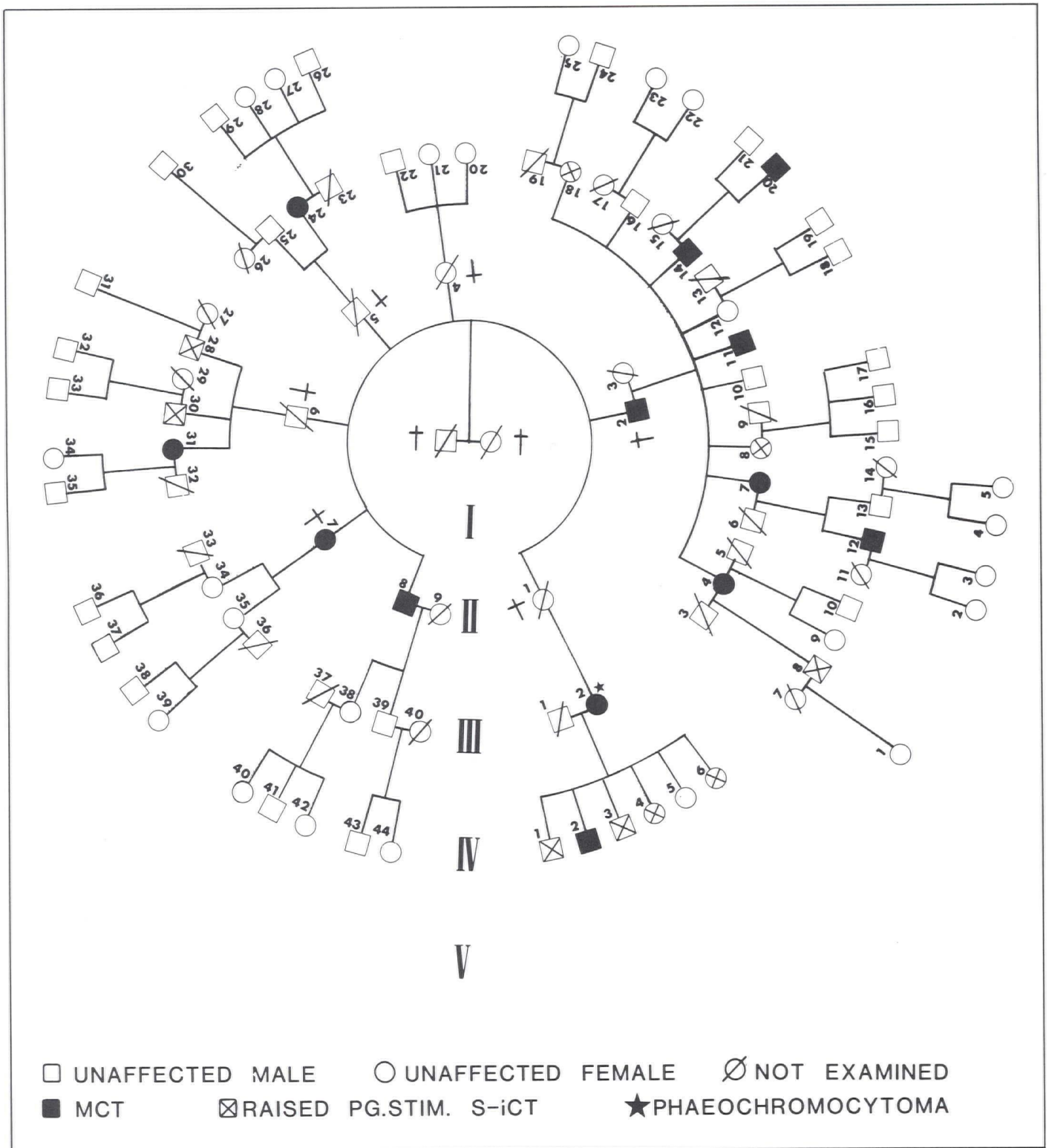


Fig. 1

Pedigree and present clinical status of a large family with MEN-2A. MTC: medullary thyroid cancer; PG.STIM. S-iCT: pentagastrin-stimulated serum immunoreactive calcitonin.

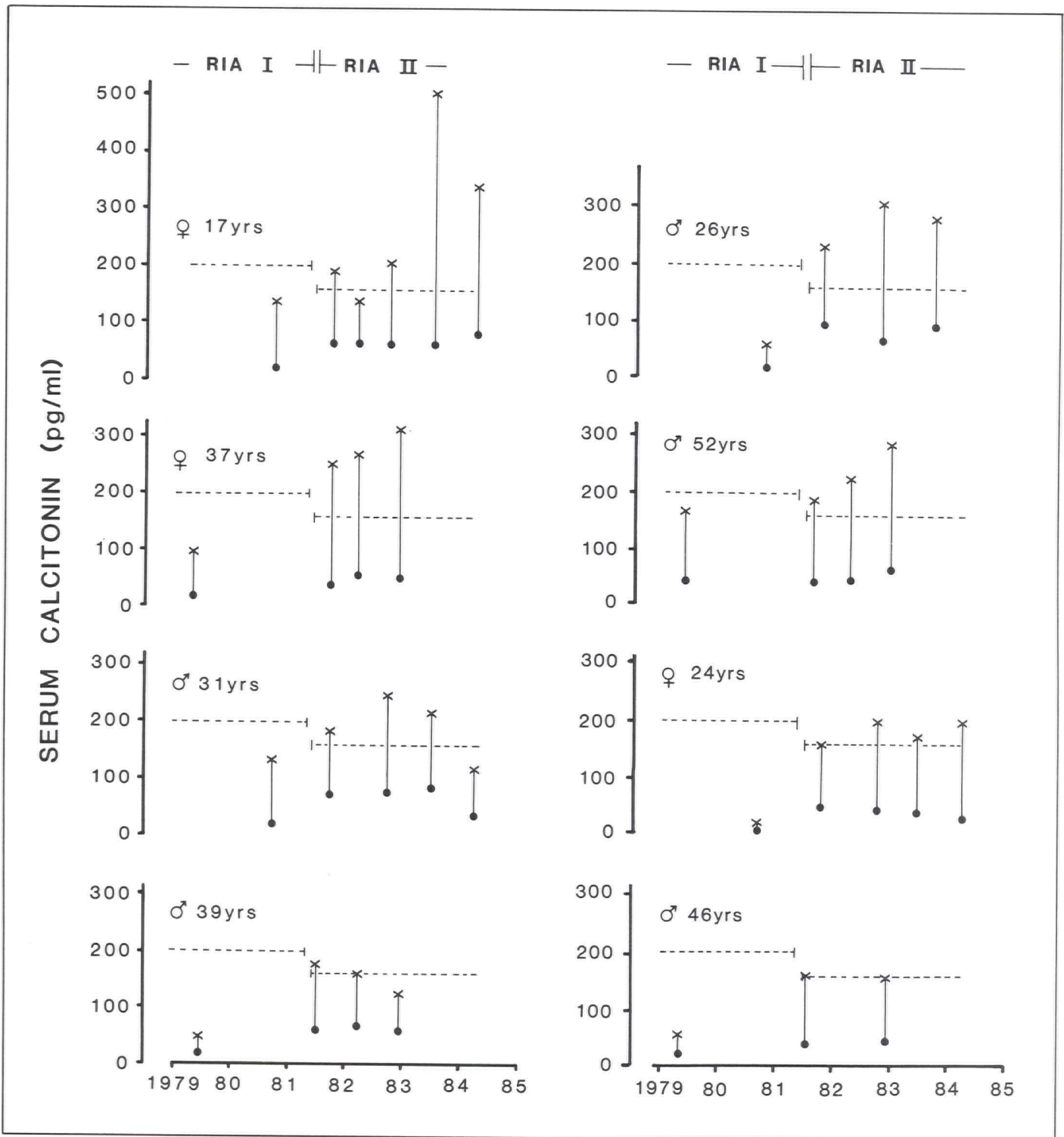


Fig. 2

Corresponding values for basal (●) and pentagastrin-stimulated (x) serum calcitonin in eight subjects belonging to one MEN-2A family. Ages at most recent investigation are indicated. Two different radioimmunoassays for calcitonin were used (RIA I before and RIA II after May, 1981). Broken horizontal lines indicate upper normal ranges for pentagastrin-stimulated serum calcitonin in the two assays.

Treatment

We believe that C-cell hyperplasia or a small MTC is the cause for elevated poststimulated serum calcitonins in these eight subjects, but thyroidectomy was not undertaken because the indications for aggressive treatment of MTC in this family seem doubtful. The medical histories of relatives who died before MEN-2A was found revealed no deaths from thyroid malignancies, although during the prospective study period, metastasizing MTC was the cause of death in one 43-year-old man. In the remaining family members with untreated MTC or residual tumor after thyroidectomy, MTC caused no mortality or morbidity, and several affected family members reached advanced ages, including two who died at age 82 and 74 from unrelated causes. Thus, MTC in this family is usually a low grade malignant disease, compatible with a normal life span and only occasionally aggressive. Accordingly, our surgeon hesitates to perform thyroidectomy in asymptomatic family members with elevated poststimulated serum calcitonin. A similar opinion has been expressed by others (12). On the other hand, the clinical course of MTC cannot be predicted when the diagnosis is made by elevated poststimulated serum calcitonin levels, and cure can be regularly achieved by thyroidectomy at this stage (2,11,13). When MTC has grown to a size evident by physical examination, more than 50% of the patients cannot be cured by surgery (13), and curative treatment of aggressive, metastasizing MTC is not currently possible. Therefore, I generally agree with most investigators that early diagnosis and treatment are necessary.

The unilateral pheochromocytoma removed in 1966 is the only such tumor detected in this family. This low prevalence of pheochromocytomas stresses the importance of continuous surveillance for these elusive tumors even in MEN-2A families where they seem to be absent. Pheochromocytomas pose a serious threat to life and should be detected and removed.

MEN-2A, Family II

MEN-2A with complete expression was recently found in a 40-year-old woman. Two of her three teenage children (16 and 19 years old) were affected (MTC plus

pheochromocytoma in one, MTC alone in one). Elevated serum calcitonin levels were demonstrated in an older, maternal half-brother of the index case, indicating that their mother had been an MEN-2A carrier. She died at age 53 without clinical signs of MEN-2A.

MEN-2B

MEN-2B with complete expression was found in a 34-year-old woman. None of six first-degree relatives, including her children (10 and 11 years old), were affected. Thus, familial occurrence could not be demonstrated, as has been the case for approximately 50% of reported patients (14,15). MTC of MEN-2B is definitely considered a malignant disease, and early diagnosis and treatment are mandatory (2,15,16).

Linkage and Chromosome Studies

The nature and chromosomal localization of the genetic defect of MEN-2A has not been determined. Adequate high-resolution chromosome studies of seven affected individuals in the two MEN-2A families (17) did not reveal an interstitial deletion within band 20p12.2, as has been reported by Babu, Van Dyke and Jackson (18). Furthermore, in carriers and noncarriers of MEN-2A in Family I, analysis of 25 different genetic marker systems within tissue types, blood groups, serum enzyme and protein markers identified for none of the systems, lod scores that would suggest linkage between the marker and MEN-2A loci (17). Thus, the diagnosis of MTC or of pheochromocytomas is identified only by repetitive investigation of all family members at risk at this time. Prospective surveillance should begin in childhood and continue until the age of approximately 40 years.

Acknowledgment

The author's participation in the First International MEN-2 Workshop was supported by the Hospital for Sick Children Foundation in Toronto.

References

1. Telenius-Berg M. Diagnostic studies in medullary carcinoma of the thyroid (Thesis). University of Lund, 1976.
2. Sizemore GW, Carney JA, Heath H III. Epidemiology of medullary carcinoma of the thyroid glands: A 5-year experience (1971-1976). *Surg Clin North Am* 1977;57:633-45.
3. Block MA, Jackson CE, Greenawald KA, Yott JB, Tashjian AH Jr. Clinical characteristics distinguishing hereditary from sporadic medullary thyroid carcinoma. *Arch Surg* 1980;115:142-8.
4. Emmertsen K, Ernø, Henriques U, Schrøder HD. C-cells for differentiation between familial and sporadic medullary thyroid carcinoma. *Dan Med Bull* 1983;30:353-6.
5. Wolfe HJ, DeLellis RA. Familial medullary thyroid carcinoma and C-cell hyperplasia. *Clin Endocrinol Metab* 1981;10:351-65.
6. Gibson WGH, Peng T-C, Croker BP. Age-associated C-cell hyperplasia in the human thyroid. *Am J Pathol* 1982;106:388-93.
7. Emmertsen K, Elbrønd O, Neilsen HE, et al. Familial medullary thyroid carcinoma in multiple endocrine neoplasia (MEN) IIa: Diagnosis and problems in treatment. *Eur J Cancer Clin Oncol* 1982;18:645-50.
8. Gagel RF, Jackson CE, Block MA, et al. Age-related probability of development of hereditary medullary thyroid carcinoma. *J Pediatr* 1982;101:941-6.
9. Nielsen HE. Uremic bone disease before and after renal transplantation. Clinical and biochemical aspects, bone mineral content and bone morphometry (Thesis). *Dan Med Bull* 1982;29:58-80.
10. Emmertsen K, Marqvorsen J, Jensen FT, Hansen HH. Radioimmunoassay of calcitonin in unextracted human serum: A sensitive method. *Scand J Clin Lab Invest* 1982;42:539-44.
11. Graze K, Spiler IJ, Tashjian AH Jr, et al. Natural history of familial medullary thyroid carcinoma. Effect of a program for early diagnosis. *N Engl J Med* 1978;299:980-5.
12. Stevenson JC, Hillyard CJ, Spanos E, et al. Sipple syndrome: Marked variability of the disease within a family and implications for management. *Postgrad Med J* 1981;57:104-8.
13. Wells SA Jr, Baylin SB, Gann DS, et al. Medullary thyroid carcinoma: Relationship of method of diagnosis to pathologic staging. *Ann Surg* 1978;188:377-84.
14. Block MB, Roberts JP, Kadair RG, Seyfer AE, Hull SF, Nofeldt FD. Multiple endocrine adenomatosis type IIB. Diagnosis and treatment. *JAMA* 1975;234:710-4.
15. Carney JA, Sizemore GW, Hayles AB. Multiple endocrine neoplasia, type 2B. In: Ioachim HL, ed. *Pathobiol Annu* 1978; 8:105-53.
16. Norton JA, Froome LC, Farrell RE, Wells SA Jr. Multiple endocrine neoplasia type IIB. The most aggressive form of medullary thyroid carcinoma. *Surg Clin North Am* 1979;59:109-18.
17. Emmertsen K, Lamm LU, Rasmussen KZ, et al. Linkage and chromosome study of multiple endocrine neoplasia IIA. *Cancer Genet Cytogenet* 1983;9:251-9.
18. Babu VR, Van Dyke DL, Jackson CE. Chromosome 20 deletion in human multiple endocrine neoplasia types 2A and 2B: A double blind study. *Proc Natl Acad Sci USA* 1984;81:2525-8.